JOURNAL OF ENDOUROLOGY
Volume 16, Number 4, May 2002

Fluid Absorption During Percutaneous Nephrolithotomy: Does It Matter?

R. A. KUKREJA, M.S., DNB, M. R. DESAI, M.S., FRCS(Lon), FRCS(Edin), R. B. SABNIS, M.S., M.Ch., and S. H. PATEL, M.S., M.Ch.

ABSTRACT

***Background and Purpose*: Large amounts of irrigating fluid are used during percutaneous nephrolithotomy (PCNL). This use may be associated with migrating calculus debris, infection, and fluid absorption. This study evaluated the presence of fluid absorption during PCNL, its clinical and biochemical significance, and maneuvers to reduce it.**

***Patients and Methods*: Fluid absorption during PCNL was evaluated in 148 patients by estimating the expired breath ethanol concentration. Factors thought to affect the amount of fluid absorbed were studied, including the amount of irrigating fluid used, the number of nephrostomy tracts, the presence of a low-pressure system, the presence of existing tracts, and complications such as bleeding or perforation of the pelvicaliceal wall.**

***Results*: Fluid absorption was evident in all patients, although no patient had any clinical or biochemical evidence of intraoperative or postoperative electrolyte imbalance. Creating a low-pressure system by using an Amplatz sheath, reducing the amount of irrigating fluid used, and staging the procedure significantly reduced the amount of fluid absorbed.**

***Conclusions*: Fluid absorption does take place during PCNL. This may be clinically significant in patients with compromised cardiorespiratory or renal status and in pediatric patients, leading to fluid overload. Using a low-pressure system, reducing the nephroscopy time and the amount of irrigating fluid used, and staging the procedure for large renal stone burdens, especially in the presence of complications such as perforation of the pelvicaliceal system, reduces fluid absorption and avoids volume overload. Fluid absorption may also be associated with both infective and noninfective pyrexia, necessitating adequate preoperative control of urinary infection.**

INTRODUCTION

PERCUTANEOUS NEPHROLITHOTOMY (PCNL) is now a widely accepted modality of treatment for complex renal calculi, especially staghorn calculi. Large amounts of irrigating fluid are used during PCNL and may be associated with migrating calculus debris, infection, and fluid absorption. While it is a well-established fact that there is considerable fluid absorption during transurethral resection of the prostate (TURP), there is little evidence of fluid absorption in percutaneous stone surgery.[1–3] This study evaluated the extent of fluid absorption during PCNL, its clinical and biochemical significance, and maneuvers to reduce it.

PATIENTS AND METHODS

A series of 148 cases of PCNL done during the period July–December 2000 were included in this study. Of these, 95 patients were males and 53 female. The age of the patients ranged from 2 years to 71 years with an average of 43 years. All the patients had a preoperative hemogram, serum creatinine and electrolyte estimation, and urine culture and sensitivity analyses. Cardiac and respiratory status was evaluated when indicated.

Ultrasound-guided peripheral caliceal puncture was done in all the cases. The tract was sequentially dilated by serial Alken dilators. 27-F Wolf nephroscope was used in all the cases, and

Department of Urology, Muljibhai Patel Urological Hospital, Gujarat, India.

$$\bullet\ (2140 + 3430 \times \underline{\text{Eb-Ethanol I}}) \times \underline{\text{EB}} + (44 + 806 \times \underline{\text{Eb-Ethanol I}})$$

EB = Change in Ethanol conc. during a 10 min period

Eb-ETHANOL I = Ethanol at beginning of 10 min period

FIG. 1. Formula for calculation of irrigating fluid absorbed (after Hann[5]).

28 F Amplatz sheath was placed to create a low-pressure pelvicaliceal system in 124 cases. Physiologic (0.9%) saline was used as the irrigating fluid, the bag being kept at a fixed height of 45 cm above the midaxillary line. Absolute ethanol 30 mL was added to each 3-L of saline bottle, giving a net ethanol concentration of 1% in the irrigating fluid. Hulten and colleagues in 1986[4] and Hahn in 1991[5] proposed measuring breath ethanol after the addition of 1% ethanol to the irrigating solution. The linear correlation between the ethanol concentration in the expired breath and the volume of absorption makes it possible to estimate with reasonable accuracy the amount of irrigating fluid that has been absorbed.

The procedure was either staged or completed in one sitting, depending on the calculous burden, operative time, and presence of risk factors (renal insufficiency, compromised cardiac and pulmonary status). When the PCNL was staged, the tract was dilated at the initial sitting and a nephrostomy tube placed. Subsequently (48 hours later), stone disintegration was done through the matured dilated tract.

Fluid absorption was estimated every 10 minutes by measurement of the expired breath ethanol concentration (EBEC) with the help of the Alcosensor, a device that was directly connected to the endotracheal tube. A standard formula was used to convert the EBEC to the amount of irrigating fluid absorbed (Fig. 1).[5] Routine hemogram and electrolyte examinations were done at the end of the procedure. The various factors evaluated were the amount of irrigating fluid used, the number of tracts, presence or absence of a low-pressure system, the presence of existing tracts, and the appearance of complication such as bleeding or perforation of the pelvicaliceal wall. Statistical analysis was done using the chi-square test for each of these factors. The incidence of postprocedural pyrexia (fever >100°C during the immediate 24 hours) was also determined.

RESULTS

Of the 148 patients, 38 (25.6%) underwent a staged procedure. The indications for staging were a large stone burden, renal insufficiency, and the presence of turbid urine or frank pus at the initial puncture. In 110 patients (74.4%), complete clearance was achieved in a single stage. In 86 of the single-stage procedures (78%), a low-pressure system was maintained with the help of an Amplatz sheath, while 34 (30%) of these patients required more than one tract.

Fluid absorption was detected in all patients and ranged from a minimum of 44 mL to a maximum of 474 mL. The volume of fluid absorbed increased with the amount of irrigating fluid used and the duration of the procedure (Fig. 2). Placement of an Amplatz sheath with subsequently reduced pressure in the pelvicaliceal system reduced the amount of fluid absorption (Fig. 3A). The difference became statistically significant ($P < 0.05$) at higher amounts of irrigating fluid (>9 L). The presence of multiple tracts did not affect the amount of fluid absorbed ($P = 0.46$ compared with cases with single tracts with identical nephroscopy time; Fig. 3B).

Staged nephrostomy with nephroscopy through the mature dilated tract reduced the amount of fluid absorbed. Compared with cases done through a fresh tract, the difference in the amount of fluid absorbed was statistically significant ($P < 0.05$) at higher amounts (6 L and above) of irrigating fluid (Fig. 3C).

The presence of significant perforation of the pelvicaliceal wall (seven cases) and bleeding (nine cases) during the procedure was associated with increased fluid absorption, the difference becoming statistically significant ($P < 0.05$) at nephroscopy times of 50 minutes and above (Fig. 4).

No patient had any clinical or biochemical evidence of intraoperative or postoperative electrolyte imbalance. The incidence of pyrexia was 10.8% (16 cases) in our series. In nine of these patients, urine culture showed evidence of infection, while in the others, no obvious cause could be identified. Ten of the cases were associated with longed nephroscopy times (>1 hour). The average irrigating fluid absorbed in these cases was 178 mL.

DISCUSSION

During percutaneous stone surgery, systemic absorption of irrigant fluid may occur when there is extravasation of fluid caused by rupture of the renal pelvicaliceal wall.[1,2] Absorption may also occur via the vessels that open up during tract dilatation and in the kidney during stone disintegration. Another route for massive and rapid fluid absorption is leakage of fluid into the peritoneal space.[6] Because diathermy is rarely used during PCNL, the irrigation fluid is always saline and never distilled water.[7] This prevents any electrolyte imbalance, especially hyponatremia, in the presence of fluid absorption as is sometimes seen during TURP.

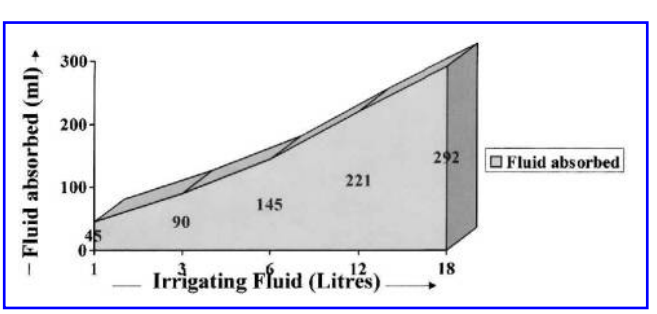

FIG. 2. Effect of amount of irrigating fluid used on absorption in 86 patients with fresh tract and Amplatz sheath.

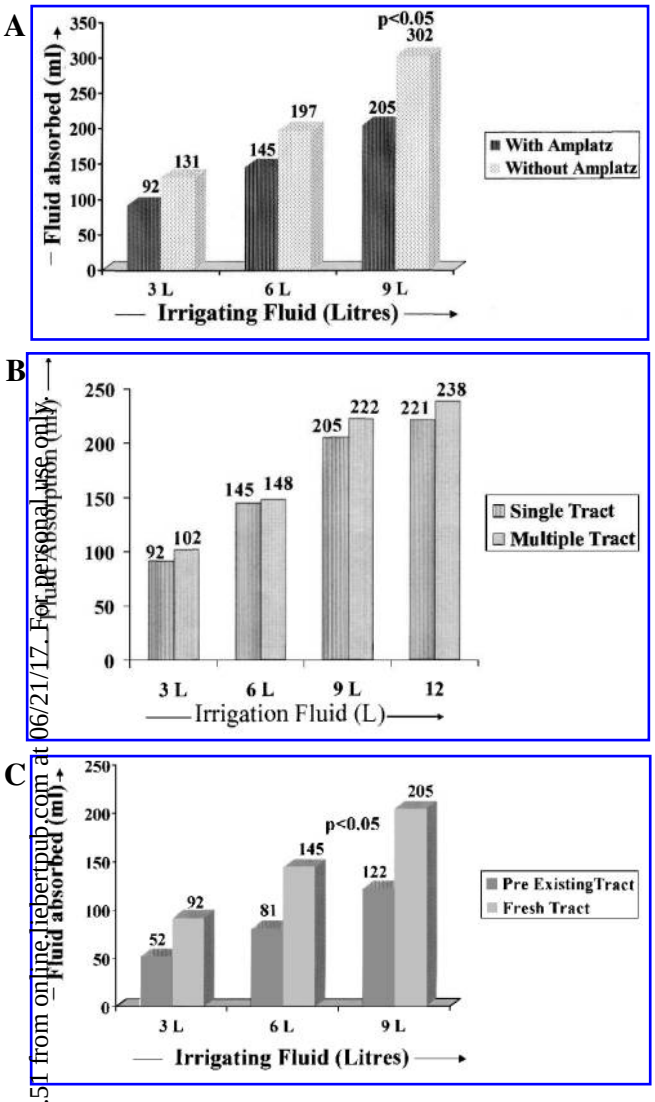

FIG. 3. Effects of procedural features. (**A**) Low-pressure system. (**B**) Multiple tracts. (**C**) Mature tract.

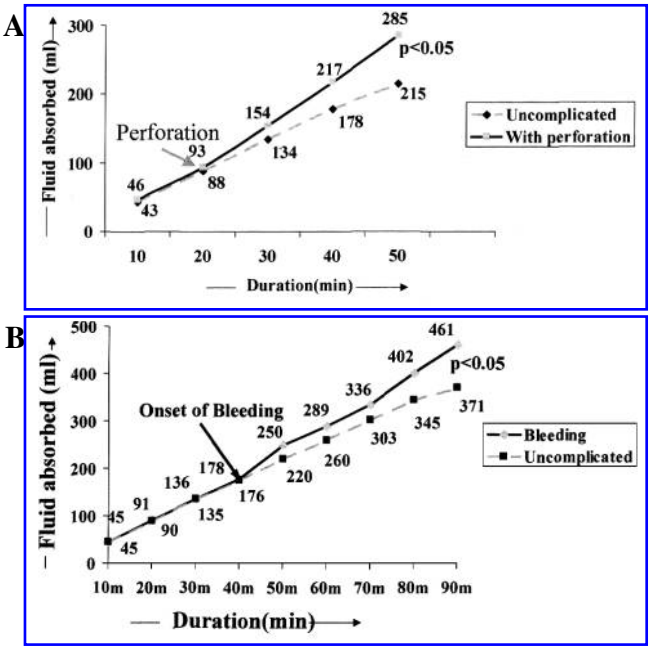

FIG. 4. Effect of complications. (**A**) Perforation. (**B**) Excessive bleeding.

Fluid absorption was evident in all the patients in our study, the maximum amount being 474 mL. None of the patients had any evidence of electrolyte imbalance or fluid overload, however. Reducing the height of the irrigating fluid bag and use of an Amplatz open drainage (low-pressure) sheath helps keep the intrapelvic pressure low and prevent fluid absorption.[7] Cases with complex renal stones or large stone burdens should be staged to reduce the amount of fluid absorbed. Staging also leads to formation of a mature nephroscopy tract and less bleeding, significantly reducing fluid absorption. Major perforations of the pelvicaliceal wall or infundibular tears allow direct access of fluid to the perinephric space and subsequent absorption. In the presence of extravasation or excessive bleeding, the procedure should be terminated and completed later. This reduces the amount of bleeding, allows the tract to mature, and reduces fluid absorption.[1]

Clinically significant volume overload may take place in patients with borderline cardiorespiratory or renal status, especially in the presence of complications such as excessive bleeding and large perforations. The procedure should always be staged in such patients with complex renal calculi. Administration of a diuretic (furosemide) at the end of the procedure would prevent volume overload in these cases.

Irrigating fluid absorption may be one of the factors responsible for infective and noninfective pyrexia after PCNL. Release of bacteria and infected material during stone fragmentation and its subsequent absorption would lead to infective pyrexia and occasionally septicemia, necessitating adequate preoperative control of urinary infection.

CONCLUSIONS

There has been little study in the literature of fluid absorption during PCNL. The occurrence of fluid absorption during PCNL and various factors affecting it have been evaluated in this study. Fluid absorption does take place during PCNL and may be clinically significant in patients with compromised cardiorespiratory or renal status and in pediatric patients, leading to fluid overload. Absorption of infected stone debris and bacteria released from the nidus of an infected stone may lead to bacteremia, fever, and, occasionally, septicemia. This can be prevented by adequate preoperative control of urinary infection and staging of the procedure in the presence of infection. Using a low-pressure nephroscopy system and reducing the nephroscopy time and the amount of irrigating fluid can reduce this problem. Staging the procedure for large renal calculi, especially in the presence of complications such as perforations and excessive bleeding, reduces fluid absorption and avoids volume overload and fever.

REFERENCES

1. Rao PN. Fluid absorption during urological endoscopy. Br J Urol 1987;60:93.
2. Clayman RV, McDougall EM, Nakada SY. Endourology of the upper urinary tract: Percutaneous renal and ureteral procedures. In: Campbell's Urology, ed. 7. Philadelphia: WB Saunders, 1997, pp 2789–2816.
3. Dunnick NR, Carson CC, Braun SD, et al. Complications of PCNL. Radiology 1985;157:51.
4. Hulten JO, Jorfeldt LS, Wictorsson YM. Monitoring fluid absorption during TURP by marking the irrigating solution with ethanol. Scand J Urol Nephrol 1986;20:245.
5. Hahn RG. Calculation of irrigant absorption by measurement of breath alcohol level during transurethral resection of the prostate. Br J Urol 1991;68:390.
6. Sinclair JF, Hutchinson A, Baraza R, et al. Absorption of 1.5% glycine after percutaneous ultrasonic lithotripsy for renal stone disease. Br Med J 1985;291:691.
7. Miller RA, Whitfield HN. Lithotripsy for renal stone disease. Br Med J 1985;291:967.

Address reprint requests to:
M.R. Desai, M.S., FRCS
Dept. of Urology
Muljibhai Patel Urological Hospital
Dr. Virendra Desai Road
Nadiad—387 001
Gujarat, India

E-mail: info@mpuh.org

This article has been cited by:

1. Tolga Karakan, Muhammet Fatih Kilinc, Omer Gokhan Doluoglu, Yildiray Yildiz, Cem Nedim Yuceturk, Murat Bagcioglu, Mehmet Ali Karagöz, Okan Bas, Berkan Resorlu. 2017. The modified ultra-mini percutaneous nephrolithotomy technique and comparison with standard nephrolithotomy: a randomized prospective study. *Urolithiasis* **45**:2, 209-213. [CrossRef]
2. Vahit Guzelburc, Mehmet Balasar, Mukaddes Colakogullari, Selcuk Guven, Abdulkadir Kandemir, Ahmet Ozturk, Pelin Karaaslan, Bulent Erkurt, Selami Albayrak. 2016. Comparison of absorbed irrigation fluid volumes during retrograde intrarenal surgery and percutaneous nephrolithotomy for the treatment of kidney stones larger than 2 cm. *SpringerPlus* **5**:1. . [CrossRef]
3. Deng Xiaolin, Song Leming, Xie Donghua, Fan Difu, Zhu Lunfeng, Yao Lei, Wang Xiaolin, Liu Shaohua, Zhang Yonghua, Liao Xiaohui, Liu Shengfeng, Peng Zuofeng, Hu Min, Zhu Xianxin, Huang Jianrong, Liu Tairong, Du Chuance, Guo Shulin, Yang Zhongsheng, Peng Guanghua, Ye Zhangqun. 2016. A Novel Flexible Ureteroscopy with Intelligent Control of Renal Pelvic Pressure: An Initial Experience of 93 Cases. *Journal of Endourology* **30**:10, 1067-1072. [Abstract] [Full Text HTML] [Full Text PDF] [Full Text PDF with Links]
4. Rivera Marcelino, Viers Boyd, Cockerill Patrick, Agarwal Deepak, Mehta Ramila, Krambeck Amy. 2016. Pre- and Postoperative Predictors of Infection-Related Complications in Patients Undergoing Percutaneous Nephrolithotomy. *Journal of Endourology* **30**:9, 982-986. [Abstract] [Full Text HTML] [Full Text PDF] [Full Text PDF with Links]
5. Mohamed Omar, Mark Noble, Sri Sivalingam, Alaa El Mahdy, Ahmed Gamal, Mohamed Farag, Manoj Monga. 2016. Systemic Inflammatory Response Syndrome after Percutaneous Nephrolithotomy: A Randomized Single-Blind Clinical Trial Evaluating the Impact of Irrigation Pressure. *The Journal of Urology* **196**:1, 109-114. [CrossRef]
6. Petrişor A. Geavlete, Dragoş Georgescu, Răzvan Mulţescu, Emanuel Alexandrescu, Mihai Drăguţescu, Florin Stănescu, Cristian Persu, Cristian Moldoveanu, Marian Jecu, Bogdan GeavletePercutaneous Approach in Renal Lithiasis 25-103. [CrossRef]
7. Shah Arvind K., Xu Kewei, Liu Hao, Huang Hai, Lin Tianxin, Bi Liangkuan, Jinli Han, Fan Xinxiang, Shrestha Rujan, Huang Jian. 2015. Implementation of Ultramini Percutaneous Nephrolithotomy for Treatment of 2–3 cm Kidney Stones: A Preliminary Report. *Journal of Endourology* **29**:11, 1231-1236. [Abstract] [Full Text HTML] [Full Text PDF] [Full Text PDF with Links]
8. Yadav Rajiv, Abhay Kumar, Yadav Poonam. 2015. Bilateral simultaneous robot-assisted pyelolithotomy for large (>6 cm) kidney stones: technique and review of literature. *Journal of Robotic Surgery* **9**:3, 263-266. [CrossRef]
9. Esam A.E. Desoky, Ehab R. ElSayed, Ahmed Eliwa, Mohamed Sleem, Waleed Shabana, Tamer Dawood, Mohamed Teleb, Salem Khalil. 2015. Flank-free Modified Supine Percutaneous Nephrolithotomy in Pediatric Age Group. *Urology* **85**:5, 1162-1165. [CrossRef]
10. Silvia Proietti, Giuseppe Sortino, Antonella Giannantoni, Mario Sofer, Roberto Peschechera, Lorenzo Giuseppe Luciani, Giuseppe Morgia, Guido Giusti. 2015. Single-session Supine Bilateral Percutaneous Nephrolithotomy. *Urology* **85**:2, 304-310. [CrossRef]
11. Zhong Wen, Leto Gioacchino, Wang Liang, Zeng Guohua. 2015. Systemic Inflammatory Response Syndrome After Flexible Ureteroscopic Lithotripsy: A Study of Risk Factors. *Journal of Endourology* **29**:1, 25-28. [Abstract] [Full Text HTML] [Full Text PDF] [Full Text PDF with Links]
12. Shuxiong Xu, Hua Shi, Jianguo Zhu, Yuanlin Wang, Ying Cao, Kai Li, Yandong Wang, Zhaolin Sun, Shujie Xia. 2014. A prospective comparative study of haemodynamic, electrolyte, and metabolic changes during percutaneous nephrolithotomy and minimally invasive percutaneous nephrolithotomy. *World Journal of Urology* **32**:5, 1275-1280. [CrossRef]

13. Ninaad S. Awsare, Maneesh Ghei, Vellore Rajkumar, Paul A. Jones. 2012. Supine percutaneous nephrolithotomy with endoscopic combined intra-renal surgery – Results of the first one hundred patients from a single UK centre. *British Journal of Medical and Surgical Urology* . [CrossRef]
14. Sarah G. Bodin, Angela F. EdwardsSpecial Anesthetic Considerations for Endourology: Ureteroscopy and Percutaneous Nephrolithotomy 120-134. [CrossRef]
15. Shashikant Mishra, Ravindra B. Sabnis, Mahesh Desai. 2012. Second Prize: Staghorn Morphometry: A New Tool for Clinical Classification and Prediction Model for Percutaneous Nephrolithotomy Monotherapy. *Journal of Endourology* **26**:1, 6-14. [Abstract] [Full Text HTML] [Full Text PDF] [Full Text PDF with Links]
16. Shashikant Mishra, Ravindra B. Sabnis, Mahesh R. Desai. 2012. Percutaneous nephrolithotomy monotherapy for staghorn. *Current Opinion in Urology* 1. [CrossRef]
17. Mohammed Lezrek, Kamal Moufid, Mohammed Asseban, Khalil Bazine, El Hassan Kasmaoui, Mohammed Alami, Amoqrane Beddouch. 2012. Reply. *Urology* **79**:1, 231-232. [CrossRef]
18. J. Stuart WolfPercutaneous Approaches to the Upper Urinary Tract Collecting System 1324-1356.e6. [CrossRef]
19. Christian Seitz, Mahesh Desai, Axel Häcker, Oliver W. Hakenberg, Evangelos Liatsikos, Udo Nagele, David Tolley. 2012. Incidence, Prevention, and Management of Complications Following Percutaneous Nephrolitholapaxy. *European Urology* **61**:1, 146-158. [CrossRef]
20. Manuel Ritter, Patrick Krombach, Maurice S. Michel. 2011. Percutaneous Stone Removal. *European Urology Supplements* **10**:5, 433-439. [CrossRef]
21. Mihir M. Desai, Rishi Grover, Monish Aron, Arvind Ganpule, Shriram S. Joshi, Mahesh R. Desai, Inderbir S. Gill. 2011. Robotic Flexible Ureteroscopy for Renal Calculi: Initial Clinical Experience. *The Journal of Urology* **186**:2, 563-568. [CrossRef]
22. Mehrdad Mohammadi Sichani, Amir H. Kashi, Shabir Al-Mousawi, Ali Tabibi. 2010. An assessment of serum sodium within 48 h after percutaneous nephrolithotomy with half-strength saline solution. *Urological Research* **38**:6, 413-416. [CrossRef]
23. Tina K. Schuster, Marc C. Smaldone, Timothy D. Averch, Michael C. Ost. 2009. Percutaneous Nephrolithotomy in Children. *Journal of Endourology* **23**:10, 1699-1705. [Abstract] [Full Text PDF] [Full Text PDF with Links]
24. Ilias Zeltser, Margaret S. Pearle, Demetrius H. Bagley. 2009. Saline Is Our Friend. *Urology* **74**:1, 28-29. [CrossRef]
25. Murat Y. Ugras, Ender Gedik, Ali Gunes, Metin Yanik, Ahmet Soylu, Can Baydinc. 2008. Some Criteria to Attempt Second Side Safely in Planned Bilateral Simultaneous Percutaneous Nephrolithotomy. *Urology* **72**:5, 996-1000. [CrossRef]
26. Wen Zhong, Guohua Zeng, Kaijun Wu, Xun Li, Wenzhong Chen, Houmeng Yang. 2008. Does a Smaller Tract in Percutaneous Nephrolithotomy Contribute to High Renal Pelvic Pressure and Postoperative Fever?. *Journal of Endourology* **22**:9, 2147-2152. [Abstract] [Full Text PDF] [Full Text PDF with Links]
27. Marco De Sio, Riccardo Autorino, Giuseppe Quarto, Francesco Calabrò, Rocco Damiano, Francesco Giugliano, Salvatore Mordente, Massimo D'Armiento. 2008. Modified Supine versus Prone Position in Percutaneous Nephrolithotomy for Renal Stones Treatable with a Single Percutaneous Access: A Prospective Randomized Trial. *European Urology* **54**:1, 196-203. [CrossRef]
28. B. Doré. 2008. Facteurs de risques et prise en charge des complications de la néphrolithotomie percutanée. *EMC - Urologie* **1**:1, 1-9. [CrossRef]
29. Rishi Nayyar, Pankaj Wadhwa, Ashok K. Hemal. 2007. Pure robotic extended pyelolithotomy: cosmetic replica of open surgery. *Journal of Robotic Surgery* **1**:3, 207-211. [CrossRef]
30. Udo Nagele, Marcus Horstmann, Karl-Dietrich Sievert, Markus A. Kuczyk, Ute Walcher, Jörg Hennenlotter, Arnulf Stenzl, Aristotelis G. Anastasiadis. 2007. A Newly Designed Amplatz Sheath Decreases Intrapelvic Irrigation Pressure During Mini-Percutaneous Nephrolitholapaxy: An in-Vitro

Pressure-Measurement and Microscopic Study. *Journal of Endourology* **21**:9, 1113-1116. [Abstract] [Full Text PDF] [Full Text PDF with Links]

31. Vsevolod Rozentsveig, Endre Z. Neulander, Efim Roussabrov, Andrei Schwartz, Leonard Lismer, Boris Gurevich, Yosef Klein, Natan Weksler. 2007. Anesthetic considerations during percutaneous nephrolithotomy. *Journal of Clinical Anesthesia* **19**:5, 351-355. [CrossRef]
32. Zeng Guohua, Zhong Wen, Li Xun, Chen Wenzhong, He Yongzhong, He Zhaohui, Lei Ming, Wu Kaijun. 2007. The Influence of Minimally Invasive Percutaneous Nephrolithotomy on Renal Pelvic Pressure In Vivo. *Surgical Laparoscopy, Endoscopy & Percutaneous Techniques* **17**:4, 307-310. [CrossRef]
33. Jee Ahn Kim, Kyung Hwa Kwak. 2007. Acute Pulmonary Edema after Simultaneous Bilateral Percutaneous Nephrolithotomy - A case report -. *Korean Journal of Anesthesiology* **53**:2, 270. [CrossRef]
34. B. Doré. 2006. Facteurs de risques et prise en charge des complications de la néphrolithotomie percutanée. *Annales d'Urologie* **40**:3, 149-160. [CrossRef]
35. B. Doré. 2006. Factores de riesgo y tratamiento de las complicaciones de la nefrolitotomía percutánea. *EMC - Urología* **38**:2, 1-10. [CrossRef]
36. Noah SchenkmanComplications of ureteroscopy and percutaneous renal surgery 755-768. [CrossRef]
37. Peter Cybulski, R. John D'A. Honey, Dr. Kenneth Pace. 2004. Fluid Absorption during Ureterorenoscopy. *Journal of Endourology* **18**:8, 739-742. [Abstract] [Full Text PDF] [Full Text PDF with Links]
38. C Sandhu, K.M Anson, U Patel. 2003. Urinary Tract Stones—Part II: Current Status of Treatment. *Clinical Radiology* **58**:6, 422-433. [CrossRef]
39. Gerhard J. Fuchs, J Paul Yurkanin. 2003. Endoscopic surgery for renal calculi. *Current Opinion in Urology* **13**:3, 243-247. [CrossRef]